

# Massive bilateral chronic subdural haematoma after ventriculoperitoneal shunt

Amit Agrawal, MCh

Department of Surgery, Datta Meghe Institute of Medical Sciences, Sawangi, Wardha, India

Bhushan Lakhkar, MD

Brij Raj Singh, DMRD

Department of Radiology, Datta Meghe Institute of Medical Sciences

A 12-year-old boy who had previously undergone a right ventriculoperitoneal shunt for obstructive hydrocephalus secondary to congenital aqueductal stenosis, presented with headache and vomiting (and no localising neurological signs). The shunt chamber was collapsed and did not fill even after applying pressure. His symptoms were suspected to be the result of shunt malfunction; however, a computed tomography (CT) scan revealed a massive bilateral subdural haematoma (Fig. 1). The child's condition deteriorated, and he developed weakness of the left upper arm, despite a bilateral burr hole and haematoma evacuation. He improved after insertion of a drain into the subdural space and catheter ligation (Fig. 2) and still further when the shunt was replaced with a high-pressure shunt system (Fig. 3). His headache and vomiting subsided, and he remains asymptomatic at follow-up.

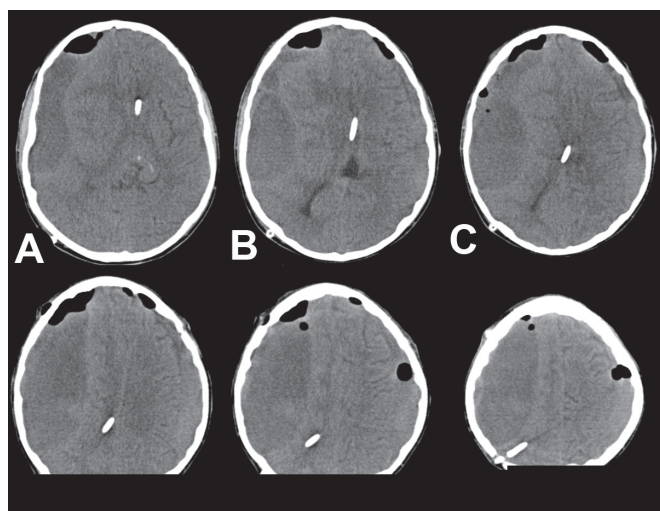


Fig. 1. CT brain scan showing marked bilateral subdural haematoma (more to the right than the left) with midline shift to the left, and distorted and collapsed ventricles.

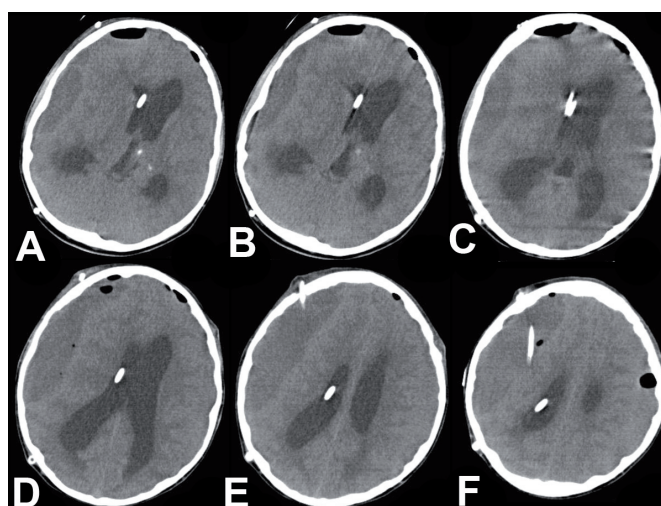


Fig. 2. After ligating the shunt, there was an increase in the size of the ventricles and a reduction in the size of the haematoma.

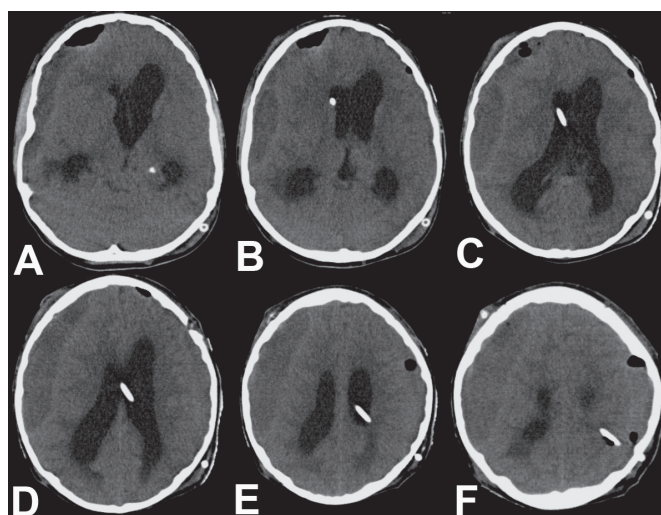


Fig. 3. After inserting the high-pressure shunt system, there was a further decrease in the size of the haematoma.