

An audit of paediatric nasal foreign bodies in Ilorin, Nigeria

O A Afolabi, FWACS
 A O Suleiman, FWACS
 S K Aremu, MB BS
 A P Eletta, FWACS
 B S Alabi, FWACS
 S Segun-Busari, FWACS
 A D Dunmade, FWACS
 F E Ologe, FWACS

University of Ilorin and University of Ilorin Teaching Hospital, Ilorin, Nigeria

Corresponding author: O A Afolabi (droaafolabi@yahoo.com)

Background. Children with nasal foreign bodies are commonly seen in everyday practice. The aim of this study was to document the pattern of foreign bodies in the nose, their treatment and outcome.

Methods. This was a prospective audit of all children seen in the ear, nose and throat clinic, accident and emergency unit and emergency paediatric unit at the University of Ilorin Teaching Hospital, Nigeria, from August 2005 to July 2006.

Results. Of a total of 173 patients with ear, nose and throat foreign bodies seen during the study period, 71 patients had foreign bodies in the nose. The male/female ratio was 1.5:1 and the mean age was 2.5 years (range 1 - 15 years), under-5s comprising 72% of the patients. The most common foreign bodies were grains and seeds (35%). Presentation was within 24 hours in 45% of cases, between 1 and 5 days in 27%, and longer in the rest. Of the patients 51% had inserted the foreign body into the nose themselves, and in 39% of cases this had happened at school. In most cases (68%) the foreign body had been inserted into the right nostril. Most children had an offensive nasal discharge (45%) or were asymptomatic (27%). Parents were the first to make the diagnosis in 63% of cases, and in 32% of cases removal had been attempted before presentation.

Most of the foreign bodies (89%) were mechanically extracted with a Jobson-Horne probe. In 61% of cases removal was done by a senior registrar. General anaesthesia was needed in a minority of cases. Minimal epistaxis after removal occurred in 50.7%, and only 1 patient had septal perforation.

Conclusion. Nasal foreign bodies are still a challenge among under-5s. Public health education is needed to make parents and caregivers aware that it is hazardous for a child to insert a foreign body into the nose. Consistent with published guidelines, the majority of cases can be managed safely with direct extraction in the office setting. With adequate training, primary health care practitioners can manage most cases successfully and will know when to refer complicated ones.

Nasal foreign bodies are common problems in children,^{1,2} especially those aged between 2 and 3 years.³ They may enter the nose through various routes, the commonest being the anterior nares or the posterior choanae, but have also been inserted through penetrating wounds and nasal surgery.⁴ Foreign bodies may be organic or inorganic.³ They may end up in any part of the nasal fossa, but are most commonly found in the vestibule and on or near the floor of the nasal fossa.⁴

Some foreign bodies are inert and may remain in the nose for months to years without mucosal reactions, while others cause inflammation, rhinolith formation and infection, with or without fetid mucopurulent nasal discharge,^{3,5} which usually result in early presentation. Prolonged unilateral nasal discharge almost always indicates a nasal foreign body.^{4,6,7}

Nasal foreign bodies vary widely in type, shape and size, and all these factors determine the degree of nasal obstruction, discomfort, time of presentation and management. Various methods of foreign body removal, employed by both otolaryngologists and non-otolaryngologists, have been reported.⁶ Positive-pressure methods with forceful expulsion of air through the nostril have been described.^{6,7} The 'parent's kiss' is a technique in which a parent uses his or her mouth

to apply positive pressure into the patient's mouth while simultaneously occluding the unaffected nostril.^{1,7-10} A similar technique involves the use of an Ambu bag instead of the 'kiss' to blow air into the mouth.¹¹ Positive pressure can also be created by blowing air into the contralateral nostril while blocking the mouth.^{12,13} Normal saline inserted with a bulb syringe has also been found effective in creating positive pressure.¹⁴

Other documented methods of removal include using surgical forceps¹⁵ for foreign bodies such as paper, cotton or foam, or a spherical hook for hard, irregularly shaped objects.⁷ Hooks made out of paper clips or hair pins have been described,¹⁶ and Hanson and Stephens¹⁷ used cyanoacrylate applied to the end of a plastic swab stick. Others have used catheters such as Foley catheters, Fogarty vascular catheters or Fogarty biliary balloons.¹⁸ The success of these tools led to the development of a disposable catheter called the Katz extractor, specifically made for removing foreign bodies from the nose and ear.¹⁹

The aim of this audit was to document the pattern of foreign bodies in the nose in children seen in our department, their treatment and outcome.

Materials and methods

This was a prospective audit of all patients with foreign bodies in the nose seen in the ear, nose and throat clinic, accident and emergency unit and emergency paediatric unit of the University of Ilorin Teaching Hospital, Ilorin, from August 2005 to July 2006. Demographic data, clinical diagnosis, site of foreign body, category of doctor who treated the patient, type of treatment and complications either before or after removal were recorded for all patients with nasal foreign bodies seen during the study period.

Results

Of a total of 173 patients with ear, nose and throat foreign bodies, 71 (41%) had foreign bodies in the nose. There were 42 males (59%) and 29 females (41%), giving a male/female ratio of 1.5:1. The mean age was 2.5 years (range 1 - 15 years), the majority of children being under 5 years of age (Table I). Most of the children (79%) were of school age or attending a day-care centre, while the rest (21%) did not yet attend school.

TABLE I. AGE OF PATIENTS WITH A NASAL FOREIGN BODY

Age (yrs)	N	%
<5	51	72
5 - 10	16	22
>10 - 15	4	6
Total	71	100

Of the children 58% lived with their parents, 26% with their grandparents, and the remaining 16% with caregivers such as Qu'ranic teachers and distant relatives at the time of the foreign body insertion.

The most common foreign bodies were grains or seeds (35%), but toys/plastics, cotton wool/foam, stones, etc. were also seen (Fig. 1). Of the patients 20% were seen within 5 hours of the incident and 45% within 24 hours (Table II).

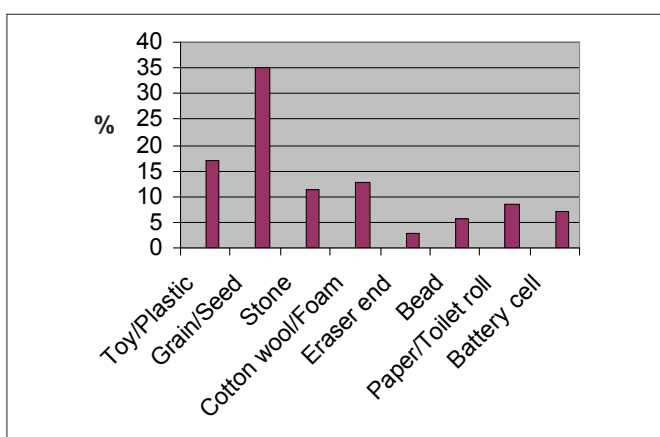


Fig. 1. Types of foreign body.

Fifty-one per cent of the children had inserted the foreign body into the nostril themselves and in 49% of cases it had been inserted by playmates. In 68% of cases the foreign body was in the right nostril, in 31% in the left nostril, and in 1% in both nostrils. Insertion had occurred at school in 39% of cases, at a

TABLE II. TIME ELAPSED BEFORE PRESENTATION WITH A NASAL FOREIGN BODY

0 - 5 h	14 (20%)
6 - 24 h	18 (25%)
1 - 5 d	19 (27%)
>5 d - <2 wks	17 (24%)
2 wks - <1 mo.	1 (1%)
≥1 mo.	2 (3%)
Total	71 (100%)

day-care centre in 21%, and at home in 17%; 23% of children could not remember where it had occurred.

Of the patients 45% presented with an offensive nasal discharge, 13% with epistaxis, 10% with pain in the nose, and 5.6% with combinations of symptoms; 27% were asymptomatic.

The majority of the nasal foreign bodies were removed by registrars (Fig. 2). Most (89%) of the removal were done using a Jobson-Horne probe with the patient immobilised, and only a minority (11%) under general anaesthesia. Epistaxis was the commonest complication after removal (Table III). Of the foreign bodies removed under general anaesthesia 75% were removed through the nose, while only 25% were pushed backward into the postnasal space and removed through the mouth.

No deaths or prolonged morbidity were recorded during the study period.

Discussion

Nasal foreign bodies requiring removal are common in children.^{1-3,7} As has been found in other studies, most of our patients were under 5 years of age.^{3,5,20} This is the age at which children tend to explore their body cavities, especially the nose, ears and mouth. Insertion of nasal foreign bodies in adults is usually associated with mental retardation.

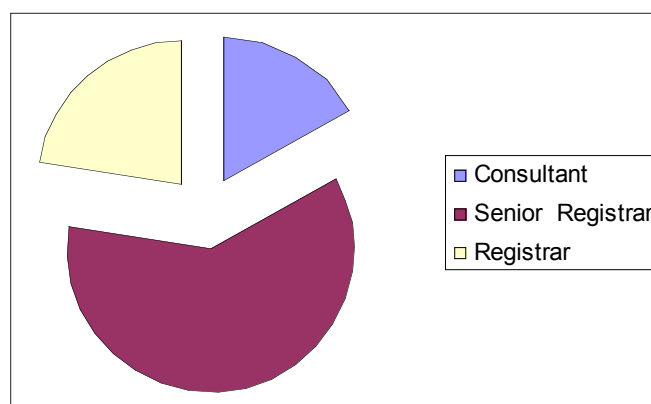


Fig. 2. Categories of doctors who removed the foreign bodies.

TABLE III. COMPLICATIONS AFTER FOREIGN BODY REMOVAL

Complication	N	%
Epistaxis	36	51
Septal perforation	1	1
None	34	48
Total	71	100



Older children may conceal their discomfort for fear of being reprimanded.

Our finding of a male preponderance (in contrast to an earlier Ibadan study) has also been reported by others.^{3,5} Who the child resides with did not seem to affect foreign body insertion, as the majority of our patients lived with their parents. We found that most episodes had occurred at school, which may be related to peer group influence; interestingly, however, one study reported that the majority of insertions of foreign bodies into the ear took place at home.²¹

Less than a quarter of our patients presented within 6 hours of insertion of the foreign body and just under half presented within 24 hours. This contrasts with studies elsewhere, in which the majority presented within 24 hours.³ Because the patient is able to breathe through the other nostril there may be minimal interference with function, especially if the object inserted into the nasal cavity is inert. Older children may conceal their discomfort for fear of being reprimanded by parents and caregivers. About 3% of our patients presented months after insertion, with a foul-smelling odour and unilateral mucopurulent nasal discharge. Concretion (rhinolith formation)^{3-5,15,22} was noted in one patient, who had plastic toy material in the nose.

The commonest foreign bodies in our series were grains/seeds, as also reported by Ogunleye and Sogebi²⁰ in Ibadan. Bean, maize and orange seeds are commonly found in African homes, in contrast to studies elsewhere.¹⁵ Beads (5.6%) were rarely found in our study, though they are available in most homes either as religious symbols (Catholic rosaries) or for cultural use.

The commonest site of insertion was the right nostril (two-thirds of cases), which is similar to findings elsewhere^{3,20} and consistent with the right hand being dominant in the majority of people. In only one patient were both nasal cavities involved. Others have also found this to be rare.^{15,23}

The majority of our patients were either asymptomatic or presented with an offensive nasal discharge; only a few had epistaxis or pain. The latter were generally due to attempts at removal at home or at a primary health care facility.^{24,25}

Most of the foreign bodies were removed through the anterior nasal cavity with instruments at presentation in our department, in line with published guidelines.^{3,7} The child is seated on the mother's lap in the examination chair. The arm and trunk are held securely, with the right arm and head immobilised by the left arm. In the few cases where the child needs to be in a supine position, he or she is wrapped in a bed sheet to immobilise the upper extremity and trunk. An assistant firmly stabilises the head and another assistant holds the feet. Under good visualisation a Jobson-Horne probe is introduced beyond the foreign body, which is retrieved with gentle traction. Most removals were done by experienced senior registrars and consultants. In only 2 cases was the foreign body dislodged into the nasopharynx under general anaesthesia, with a hypopharyngeal pack in place to prevent

aspiration, and removed via the mouth. In our centre removal of a foreign body under general anaesthesia costs about 10 times more than removal in an office setting.²¹

The complications of nasal foreign body relate to the length of time it is lodged in the nose, unskilled attempts at removal, and its size and shape.^{7,15} The commonest complications are epistaxis, septal or nasal mucosa ulceration, and septal abscess. Septal perforation is uncommon, as observed in our study. Other complications are nasal or choanal stenosis. We had no case of nasal foreign body aspiration; however, this can result from incorrect technique, inexperience, or inadvertent inhalation instead of exhalation when using the positive-pressure method.⁶⁻¹⁰

Published guidelines^{3,7} on the removal of nasal foreign bodies include:

1. Confirmation of the presence of the foreign body from the history and examination of the anterior nares with a head mirror or electric head lamp. NB: The first attempt at removing the foreign body will be the best, and will often be the only attempt the child will allow.
2. Removal is best accomplished with a wax hook, eustachian tube catheter or cupped forceps for thin objects such as buttons or soft organic objects such as sponge. In our study a Jobson-Horne probe was used.
3. The nasal cavity must always be examined afterwards, as there may be a second foreign body further up the nose.
4. Removal is usually an outpatient procedure, and antibiotics can be used at the physician's discretion.

There is a need for public health education to alert parents and caregivers to the hazards of nasal foreign body insertion, and for continued education of primary care physicians to enable them to manage cases safely or refer them promptly, especially when the foreign body is not well visualised or there are complications. In 32% of cases in our study removal had been attempted by a non-specialist and had failed. It is not possible to estimate from our data whether the management and referral of these patients was appropriate. The 24-hour availability of an otorhinolaryngologist at our centre may have contributed to the direct referral of many of our patients.²⁶

Nasal foreign bodies are still a challenge among under-5s. However, with adequate training and skill a high proportion of cases can be managed safely in the office setting. Otolaryngologists are not easily accessible in most developing countries, and primary health care management of foreign bodies needs to be assessed regularly in order to identify gaps and improve clinical outcome.

References

1. Botma M, Bader R, Kubba H. 'A parent's kiss': evaluating an unusual method for removing nasal foreign body in children. *J Laryngol Otol* 2000; 114: 598-600.
2. Kadish HA, Corneli HM. Removal of nasal foreign bodies in paediatric population. *Am J Emerg Med* 1997; 15: 54-56.
3. Roland NJ, McRae RDR, McCombe AW. *Key Topics in Otolaryngology and Head and Neck Surgery*. 3rd ed. Oxford: BIOS Scientific Publishers, 2005: 104.
4. Walby AP. Foreign bodies in the ear or nose. In: Adam DA, Ginnamond MJ, eds. *Scottbrown's Paediatric Otolaryngology*. 6th ed. Oxford: Butterworth-Heinemann, 1997: 6/14/1-6/14/6.
5. Cohen HA, Goldberg E, Horev Z. Removal of nasal foreign bodies in children. *Clin Pediatr (Phila)* 1993; 32: 192.
6. Kiger JR, Brenkert TE, Losek JD. Nasal foreign body removal in children. *Pediatr Emerg Care* 2008; 24(11): 785-792.

7. Kalan A, Tariq M. Foreign bodies in the nasal cavities: a comprehensive review of the aetiology, diagnostic pointers, and therapeutic measures. *Postgrad Med J* 2000; 76: 484-487.
8. Benjamin E, Harcourt J. The modified 'parent's kiss' for the removal of paediatric nasal foreign bodies. *Clin Otolaryngol* 2007; 32: 120-121.
9. Backlin SA. Positive-pressure technique for nasal foreign body removal in children. *Ann Emerg Med* 1995; 25(4): 554-555.
10. Purohit N, Ray S, Wilson T, Chawla OP. The 'parent's kiss': an effective way to remove paediatric nasal foreign bodies. *Ann R Coll Surg Engl* 2008; 90(5): 420-422.
11. Finkelstein JA. Oral Ambu-bag insufflations to remove unilateral nasal foreign bodies. *Am J Emerg Med* 1996; 14(1): 57-58.
12. Sorrels WF. Simple noninvasive effective method for removal of nasal foreign bodies in infants and children. *Clin Pediatr (Phila)* 2002; 41(2): 133.
13. Navitsky RC, Beamsley A, McLaughlin S. Nasal positive-pressure technique for nasal foreign body removal in children. *Am J Emerg Med* 2002; 20(2): 103-104.
14. Lichenstein R, Giudice EL. Nasal wash technique for nasal foreign body removal. *Pediatr Emerg Care* 2000; 16(1): 59-60.
15. François M, Hamrioui R, Narcy P. Nasal foreign bodies in children. *Eur Arch Otorhinolaryngol* 1998; 255(3): 132-134.
16. Ezechukwu CC. Removal of ear and nasal foreign bodies where there is no otorhinolaryngologist. *Trop Doct* 2005; 35(1): 12-13.
17. Hanson RM, Stephens M. Cyanoacrylate-assisted foreign body removal from the ear and nose in children. *J Paediatr Child Health* 1994; 30(1): 77-78.
18. Fox JR. Fogarty catheter removal of nasal foreign bodies. *Ann Emerg Med* 1980; 9(1): 37-38.
19. Katz DL. Katz extractor oto-rhino foreign body remover. <http://www.inhealth.com/katz/surveyresults.htm> (accessed 3 December 2007).
20. Ogunleye AOA, Sogebi OA. Nasal foreign body in African children. *Afr J Med Sci* 2004; 33: 225-228.
21. Ologe FE, Dunmade AD, Afolabi OA. Aural foreign body in children. *Indian J Pediatr* 2007; 74(8): 755-758.
22. Tong MC, Ying SY, Vanhaselt CA. Nasal foreign bodies in children. *Int J Paediatr Otorhinolaryngol* 1996; 35: 207-211.
23. Wada I, Miskima H, Hida T, Kase Y, Limima T. Nasal foreign bodies in 299 cases. *Nippon Jibiinkoka Gakkai Kaiho* 2000; 103: 1212-1217.
24. Olatoke F, Ologe FE, Alabi BS, Dunmade AD, Segun-Busari S, Afolabi OA. Epistaxis: a 5 year review. *Saudi Med J* 2006; 27(7): 1077-1079.
25. Afolabi AO, Ologe FE. Management of epistaxis. *Postgraduate Doctor Caribbean* 2006; 22/2: 54-61.
26. Ngo A, Ngo KC, Sim TP. Otorhinolaryngeal foreign bodies in children presenting to the emergency department. *Singapore Med J* 2005; 46(4): 172-178.