

# Pattern of steroid-resistant nephrotic syndrome in children and the role of histopathology: A single-centre study

S K Pradhan,<sup>1</sup> MD, FISPAN, FPN; P P Mutalik,<sup>2</sup> MD; A K Mohanty,<sup>3</sup> MD

Sardar Vallabh Bhai Patel Postgraduate Institute of Paediatrics and Sriram Chandra Bhanja Medical College, Cuttack, Odisha, India

Corresponding author: S K Pradhan (drsubal@rediffmail.com)

**Background.** Steroid-resistant nephrotic syndrome (SRNS) is a common problem in paediatric nephrology practice. There is currently little information on the spectrum of histopathological lesions in children presenting with SRNS in India and other south-east Asian countries.

**Objective.** To determine the histopathological lesions in children presenting with SRNS at our institution.

**Methods.** The study was conducted at Sardar Vallabh Bhai Patel Postgraduate Institute of Paediatrics and Sriram Chandra Bhanja Medical College, Cuttack, Odisha, India, from January 2009 to March 2013. All children aged 1 - 14 years presenting with primary SRNS and in whom renal biopsies were performed were included in the study. Their demographic, clinical, laboratory and histopathological data were retrieved from files and original renal biopsy forms.

**Results.** A total of 40 children had a clinical diagnosis of SRNS; 23 were males and 17 females (male:female ratio 1:35). Their mean age ( $\pm$  standard deviation) was 4.47 ( $\pm$ 2.98) years (range 1 - 14 years). The histopathological lesions seen on renal biopsy specimens comprised minimal-change disease (MCD) ( $n=18$ ), focal segmental glomerulosclerosis (FSGS) ( $n=12$ ), immunoglobulin A nephropathy (IgAN) ( $n=5$ ), immunoglobulin M nephropathy ( $n=2$ ), membranous nephropathy ( $n=2$ ) and idiopathic mesangial proliferative glomerulonephritis ( $n=1$ ).

**Conclusion.** MCD is the predominant lesion in children with SRNS at our institution, followed by FSGS and IgAN.

*S Afr J CH* 2013;7(4):153-154. DOI:10.7196/SAJCH.607



Steroid-resistant nephrotic syndrome (SRNS) remains a challenge for paediatric nephrologists. The underlying histopathology usually affects the course of the disease and the response to treatment.<sup>[1]</sup> There is still controversy over the role of renal biopsy in the management of children with SRNS.<sup>[2]</sup> Studies by the International Study of Kidney Disease in Children showed focal and segmental glomerulosclerosis (FSGS), mesangial proliferative glomerulonephritis (MPGN) and minimal-change disease (MCD) to be the morphological lesions in 70%, 44% and 7%, respectively, of these children.<sup>[3]</sup> The glomerular morphological pattern of SRNS in Indian children has seldom been described, and in eastern India data on childhood nephrotic syndrome are almost non-existent because facilities where biopsies can be carried out and specialised centres for renal care are very scarce. It has therefore become necessary to determine the true pattern of the glomerulopathies underlying SRNS in a large cohort of children in this part of the world, where a major proportion of renal pathology is due to malaria. This study was designed to determine the spectrum of histopathological lesions in children with SRNS at our institution.

## Methods

This descriptive and prospective study was conducted from January 2009 to March 2013 at the Sardar Vallabh Bhai Patel Postgraduate Institute of Paediatrics and Sriram Chandra Bhanja Medical College, Cuttack, Odisha, India. A total of 40 patients with SRNS aged between 1 and 14 years were included on the basis of lack of remission despite treatment with prednisolone 2 mg/kg/day for 4 weeks as per the Indian Society of Pediatric Nephrology (ISPN) consensus guideline. Complete remission was defined as a spot urine protein/creatinine ratio (UPCR)  $<0.2$  or dipstick proteinuria  $<30$  mg/dl for 3 consecutive days. Children with congenital nephrotic syndrome, lupus nephritis and other secondary causes of nephrotic syndrome were excluded from the study. The demographic profile, clinical and biochemical parameters, histological subtypes and outcomes at 6 months were analysed. Demographic, clinical and laboratory data at the time of presentation and at last follow-up were retrieved from case files

and the histopathological data, including light microscopy (LM) and immunofluorescence (IF) findings, were recorded from the original renal biopsy forms. Standard definitions of the disease and treatment responses were based on the ISPN guideline. The LM categorisation of glomerular lesions is shown in Figs 1 - 3. Parents or legal guardians were counselled regarding the need for renal biopsy, and informed consent was obtained before obtaining ultrasound-guided percutaneous renal biopsy specimens by means of an automated biopsy gun.

## Results

Of the 40 patients, 23 were boys. The mean age of presentation ( $\pm$  standard deviation) was 4.47 ( $\pm$ 2.98) years (range 1 - 14 years). The mean serum albumin level at presentation was 1.80 ( $\pm$ 0.38) g/l. Four children had raised serum creatinine levels, and the mean serum creatinine level was 2.0 ( $\pm$ 0.18) mg/dl. All children had 4+ proteinuria on dipstick testing, the mean UPCR was 6.38 ( $\pm$ 1.47), and 8 children (20.0%) had microscopic haematuria. Renal histopathological features were compatible with MCD in 45.0% of cases ( $n=18$ ), FSGS in 30.0% ( $n=12$ ), IgA nephropathy (IgAN) in 12.5% ( $n=5$ ), IgM nephropathy in 5.0% ( $n=2$ ), membranous nephropathy in 5.0% ( $n=2$ ), and MPGN in 2.5% ( $n=1$ ). At the end of 6 months of treatment and follow-up after renal biopsy, 72.5% of the children ( $n=29$ ) were in remission, 22.5% ( $n=9$ ) were in partial remission, and 3 (7.5%) had persistent 3+ or 4+ proteinuria. Significantly more children with non-MCD (9/22) than children with MCD (2/18) continued to be proteinuric ( $p=0.035$ ), and clinical remission was better achieved in MCD than in FSGS. MCD was the predominant histopathological lesion of SRNS in our patient population.

## Discussion

SRNS is a common problem in paediatric nephrology practice, and the treatment of these children is often challenging.<sup>[4]</sup> Approximately 10 - 20% of children with nephrotic syndrome are classified as having SRNS and are at risk of progressive renal disease as well as complications due to side-effects of prolonged treatment with immunosuppressive medication.<sup>[5]</sup> Earlier

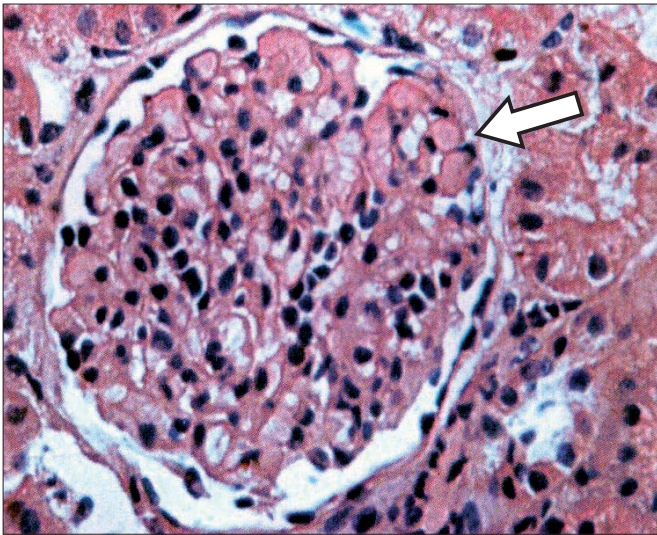


Fig. 1. Light microscopy showing a glomerulus (arrow) within the normal limit of morphology. The interstitium is mildly oedematous. The tubules are unremarkable. The histopathology is consistent with minimal-change disease.

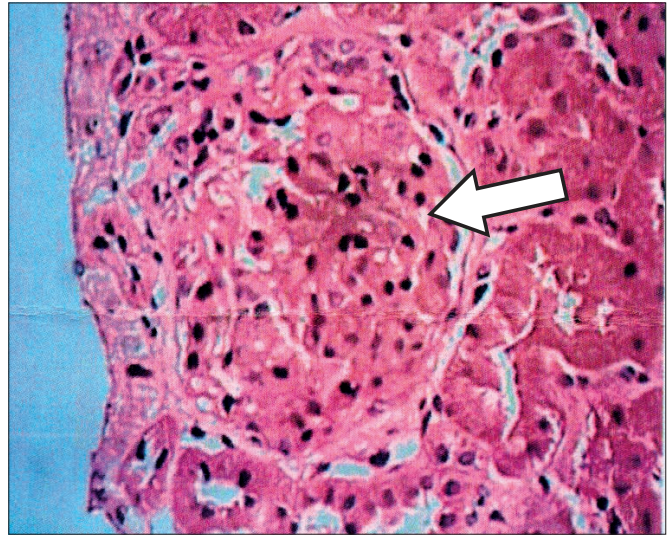


Fig. 3. Light microscopy showing one glomerulus (arrow) with matrix expansion and uniform thickening of the basement membrane. The tubules show mild atrophy. The interstitium contains patchy moderate infiltrates. The histopathological appearance is consistent with membranous nephropathy.

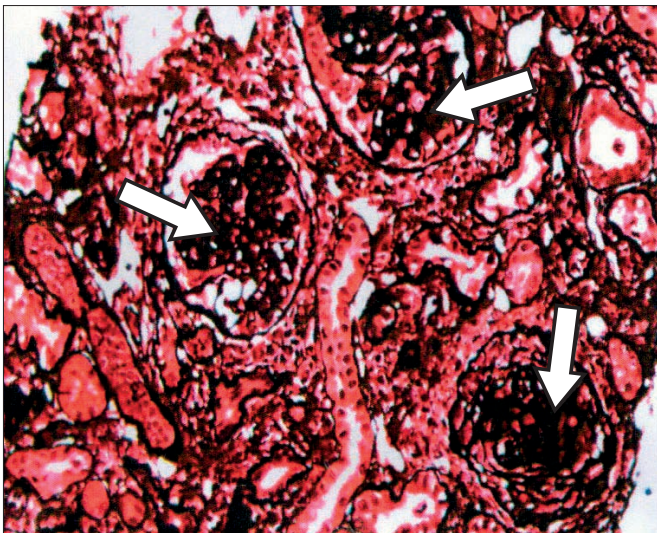


Fig. 2. Light microscopy showing three glomeruli (arrows) with segmental sclerosis of glomerular tufts, accompanied by aggregation of foam cells and proliferation of podocytes. The basement membrane is not thickened. The tubules show patchy atrophy, and the interstitium moderate mixed inflammatory cell infiltrate. The blood vessels are unremarkable. The histopathology is consistent with a classic focal segmental glomerulosclerosis.

reports have suggested that the outcome of the disease can be predicted from the clinical response to steroids, and that biopsy is unnecessary for the vast majority of children with idiopathic nephrotic syndrome.<sup>[6]</sup> There is no consensus regarding routine renal biopsy and therapeutic protocol in children with SRNS.<sup>[7-11]</sup> Various agents have been used with different outcomes.<sup>[12-15]</sup> Although the response to treatment is the best prognostic indicator in children with nephrotic syndrome, renal biopsy has a definite role and is of significant prognostic value in SRNS.<sup>[2,15]</sup>

Our study delineates the spectrum of histopathological findings in SRNS in eastern India. In conclusion, and in contrast to other studies,<sup>[1,2,4,7]</sup> our results indicate MCD to be the commonest histopathological lesion in children with SRNS, followed by FSGS and IgAN. Children with SRNS secondary to MCD are more likely than those with non-MCD to respond to therapy and achieve remission, and have a better long-term prognosis. Renal biopsy therefore has diagnostic and prognostic value in children with SRNS.

**Author contributions.** SKP: conception, manuscript review and preparation; PM: literature search, data acquisition, design and drafting; AKM: literature review and drafting.

#### References

1. Kari JA, Halawani M, Mokhtar G, Jalalah SM, Anshasi W. Pattern of steroid resistant nephrotic syndrome in children living in the kingdom of Saudi Arabia. *Saudi J Kidney Dis Transpl* 2009;20(5):854-857.
2. Gulati S, Sengupta D, Sharma RK, et al. Steroid resistant nephrotic syndrome: Role of histopathology. *Indian Pediatr* 2006;43(1):55-60.
3. International Study of Kidney Disease in Children. The primary nephrotic syndrome in children. Identification of patients with minimal change nephrotic syndrome from initial response to prednisone: A report of the International Study of Kidney Disease in Children. *J Pediatr* 1981;98(4):561-564.
4. Mubarak M, Kazi JI, Shakeel S, Lanewala A, Hashmi S. The spectrum of histopathological lesions in children presenting with steroid-resistant nephrotic syndrome at a single center in Pakistan. *The Scientific World Journal* 2012, Article ID 681802. [<http://dx.doi.org/10.1100/2012/681802>]
5. Bagga A, Mantan M. Nephrotic syndrome in children. *Indian J Med Res* 2005;122(1):13-18.
6. International Study of Kidney Disease in Children. Nephrotic syndrome in children: Prediction of histopathology from clinical and laboratory characteristics at time of diagnosis. *Kidney Int* 1978;13(2):159-165. [<http://dx.doi.org/10.1038/ki.1978.23>]
7. Olowu WA, Adelusola KA, Adefehinti O. Childhood idiopathic steroid resistant nephrotic syndrome in southwestern Nigeria. *Saudi J Kidney Dis Transpl* 2010;21(5):979-990.
8. Bagga A, Gulati A, Gulati S, Mehta KP, Vijayakumar M. Management of steroid resistant nephrotic syndrome. *Indian Pediatr* 2009;46(1):35-47.
9. Ehrlich JH, Geerlings C, Zivicnjak M, Franke D, Geerlings H, Gellermann J. Steroid resistant idiopathic childhood nephrosis: Overdiagnosed and undertreated. *Nephrol Dial Transplant* 2007;22(8):2183-2193. [<http://dx.doi.org/10.1093/ndt/gfm092>]
10. Hamasaki Y, Yoshikawa N, Hattori S, et al. Cyclosporine and steroid therapy in children with steroid-resistant nephrotic syndrome: Japanese Study Group of Renal Disease. *Pediatr Nephrol* 2009;24(11):2177-2185. [<http://dx.doi.org/10.1007/s00467-009-1264-0>]
11. Habashy D, Hodson EM, Craig JC. Interventions for steroid-resistant nephrotic syndrome: A systematic review. *Pediatr Nephrol* 2003;18(9):906-912. [<http://dx.doi.org/10.1007/s00467-003-1207-0>]
12. Kari JA, Halawani M. Treatment of steroid resistant nephrotic syndrome in children. *Saudi J Kidney Dis Transpl* 2010;21(3):484-487.
13. Mekahli D, Liutkus A, Ranchin B, et al. Long-term outcome of idiopathic steroid-resistant nephrotic syndrome: A multicenter study. *Pediatr Nephrol* 2009;24(8):1525-1532. [<http://dx.doi.org/10.1007/s00467-009-1138-5>]
14. Srivastava T, Simon SD, Alon US. High incidence of focal segmental glomerulosclerosis in nephrotic syndrome of childhood. *Pediatr Nephrol* 1999;13(1):13-18. [<http://dx.doi.org/10.1007/s004670050555>]
15. Mubarak M, Lanewala A, Kazi JI, et al. Histopathological spectrum of childhood nephrotic syndrome in Pakistan. *Clin Exp Nephrol* 2009;13(6):589-589. [<http://dx.doi.org/10.1007/s10157-009-0216-0>]