

Is Reye's syndrome still a valid diagnosis?

L du Toit-Prinsloo,¹ MB ChB, DipForMed (SA) Path, FCForPath (SA), MMed (Path) (Forens);

P Snyman,² MB ChB, DCH (SA), DipPEC (SA), FCPaed (SA); G Saayman,¹ MB ChB, FCForPath (SA), MMed (Med) (Forens)

¹ Department of Forensic Medicine, University of Pretoria, South Africa

² Department of Paediatrics, Kalafong Hospital, University of Pretoria, South Africa

Corresponding author: L du Toit-Prinsloo (lorraine.dutoit@up.ac.za)

Reye's syndrome is characterised by acute non-inflammatory encephalopathy and fatty degeneration of the liver. The exact aetiology of the syndrome is unknown, but there is an association with viral infections and the use of aspirin. There has been a sharp decline in the incidence of Reye's syndrome; the reasons for this are unclear, but may be due, in part, to the declining use of aspirin in children and to improvements in the diagnosis of underlying inborn errors of metabolism. The use of the term 'Reye-like' has been advocated among experts in the field. We report the case of a child with Reye-like syndrome complicated by pancreatitis.

S Afr J CH 2014;8(2):75-77. DOI:10.7196/SAJCH.664



Case presentation

A previously healthy 8-year-old boy was admitted to Kalafong Hospital with a 1-day history of abdominal pain and persistent vomiting. The mother had administered aspirin as symptomatic treatment. On admission there was slight epigastric tenderness, but no organomegaly or other signs of liver failure or jaundice. The neurological examination was normal. Surgical causes for the tender abdomen were excluded. Laboratory investigations revealed markedly elevated liver enzymes with normal amylase and lipase levels on admission. During the next few days his condition deteriorated rapidly. Initial lethargy progressed to coma and convulsions, requiring intubation and mechanical ventilation. The liver function deteriorated during the admission and he developed preterminal bronchopneumonia.

Investigations on admission are summarised in Table 1. The full blood count was essentially normal, C-reactive protein was 9.1 mg/l, the toxicology screen did not reveal any abnormalities and the S-acetaminophen level was <66.0 µmol/l, with the S-salicylate level <0.10 mmol/l. Investigations for hepatitis A, B, C and *Herpes simplex* were negative and the blood cultures were also negative. A lumbar puncture was not performed. The patient died 6 days after admission. A clinical diagnosis of Reye's syndrome was made. The clinical staging of Reye's syndrome was stage I on admission, and progressed to stage V over a period of 6 days.

The case was referred for a medico-legal postmortem examination in terms of section 48 of the Health Professions Amendment Act 29 of 2007 (as this was regarded as a fatality following the administration of a drug). Macroscopic postmortem examination recorded the height of the child as 1.2 m and weight as 23 kg. External examination showed the features of medical intervention (indwelling catheters, intravenous access lines) with no injuries noted to the body. Internal examination of the brain showed marked oedema with widening and flattening of the gyri and narrowing of the sulci. No features of herniation were present. The mass of the brain was 1 312 g. The liver was markedly yellow in colour with fatty change and a firm consistency with micronodular accentuation on cut sectioning. The mass of the liver was 756 g (normal for the age of the child). The pancreas appeared normal macroscopically.

Histological examination of tissue slides of the liver showed diffuse panacinar steatosis with feathery degeneration of the hepatocytes and ballooning in areas (Fig. 1). Electron microscopy

of the liver showed enlarged mitochondria with proliferation of the endoplasmic reticulum (ER). Sections of the pancreas showed acute haemorrhagic pancreatitis (Fig. 2) and bronchopneumonia was present on the lung sections.

Discussion

Reye's syndrome is characterised by acute non-inflammatory encephalopathy and fatty degeneration of the liver.^[1] Historically patients with these symptoms have been reported since 1929^[1] with Reye's syndrome first described in 1963 by Reye *et al.*^[2] in Australia.

The 'classic' picture of Reye's syndrome is stated as follows: 'a previously healthy child, aged about 7 - 9 years, acquires a viral infection, typically of the upper respiratory tract (especially influenza) or chickenpox. A few days elapse, and there may even be some recovery, but then the child becomes unwell with frequent, effortless, profuse vomiting.'^[3] Clinically the symptoms of Reye's syndrome can be divided into five stages according to the National Reye's Syndrome Foundation.^[4] Stage I includes persistent vomiting, listlessness and drowsiness. Stage II shows personality changes, and stage III confusion and disorientation. Coma can set in during stage IV and ultimately death can result during stage V.^[4]

The exact aetiology of Reye's syndrome is unknown. It is regarded as a multifactorial disease that can follow viral illness.^[5] The association of Reye's syndrome after the administration of aspirin is well known. Porter *et al.*^[5] reported a marked decline in the incidence of Reye's syndrome in the UK after a public warning regarding the association of aspirin with Reye's syndrome. In South Africa (SA) the use of non-therapeutic aspirin in children is still regarded as problematic, with at least 21 children admitted to the Red Cross War Memorial Children's Hospital over an 18-month period from January 2006 after receiving aspirin.^[6]

A diagnosis of Reye's syndrome includes a review of the available history as well as laboratory investigations. The electron microscopic features of the liver tissue have always been regarded as pathognomonic in diagnosing Reye's syndrome.^[3] Changes include proliferation of the ER and alterations in the mitochondria, including matrix expansion, loss of the dense granules and the development of pleomorphic shapes.

Pancreatitis has been documented in several cases of Reye's syndrome. One study done at the Indiana University Hospital indicated pancreatitis in 18 patients with Reye's syndrome.^[7] The study emphasised that patients need to be monitored carefully, based on findings that a subgroup had no clinical or laboratory indication of pancreatitis.

CASE REPORT

Table 1. Investigations on admission

Chemistry	
Sodium	137 mmol/l
Potassium	6.1 mmol/l (4.5 mmol/l*)
Chloride	99 mmol/l
Carbon dioxide	17 mmol/l
Urea	5.2 mmol/l
Creatinine	56 µmol/l
Anion gap	27 mmol/l (20 mmol/l*)
Calcium	2.11 mmol/l
Magnesium	1.02 mmol/l
Inorganic phosphate	1.84 mmol/l
LFTs	
Bilirubin (total)	11 µmol/l
Bilirubin (conjugated)	7 µmol/l
Total protein	72 g/l
Albumin	36 g/l
GGT	49 U/l
ALT	1 100 U/l
AST	958 U/l
ALP	308 U/l
Ammonia*	266 µmol/l
Coagulation studies	
PT	29.10 s (N=10 - 14)
INR	2.30 (N=0.90 - 1.20; therapeutic=2.00 - 3.00)
PTT	34.80 s (N=26 - 36)
Serum enzymes	
Amylase	25 U/l (N=25 - 125)
Lipase	55 U/l (N=114 - 286)
LDH*	1 130 U/l

LFTs = liver function tests; GGT = gamma-glutamyl transferase; ALT = alanine transaminase; AST = aspartate transaminase; ALP = alkaline phosphatase; PT = prothombin time; INR = international normalised ratio; PTT = partial thromboplastin time; LDH = lactate dehydrogenase.

* Values from day 2.

In the US, a total of 1 207 cases of Reye's syndrome were reported from 1981 to 1997.^[1] The latter study also indicates the decline in the incidence of Reye's syndrome over the study period. In 1980, 555 cases were reported with no more than two cases per year from 1994 until 1997.^[1] The decline in the number of cases can be ascribed to improved diagnostic testing for underlying inborn errors of metabolism (IEM), the most common being medium-chain acyl-coenzyme A dehydrogenase deficiency, as well as public awareness regarding the use of aspirin in children.^[1,3]

In recent years, the existence of Reye's syndrome has been questioned. Numerous studies have reviewed cases previously diagnosed as Reye's syndrome and have changed the diagnosis after the application of newer diagnostic tests for IEM.^[8] A workshop on Reye's syndrome and Reye-like inherited metabolic disorders held in Doncaster in the UK in 2002 suggested the term Reye-like syndrome.^[9]

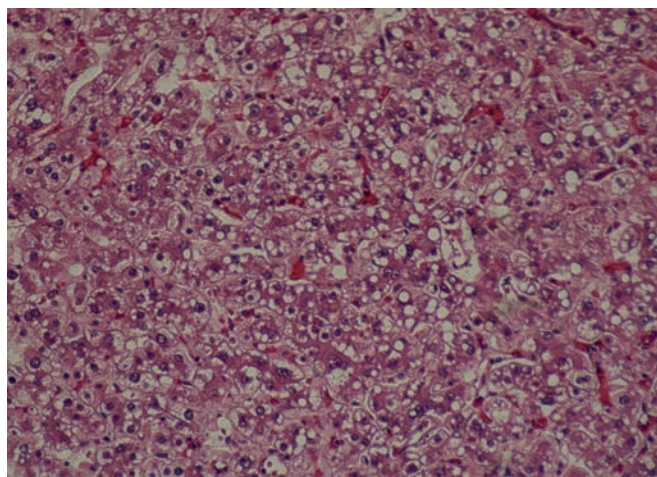


Fig. 1. Histology of the liver.

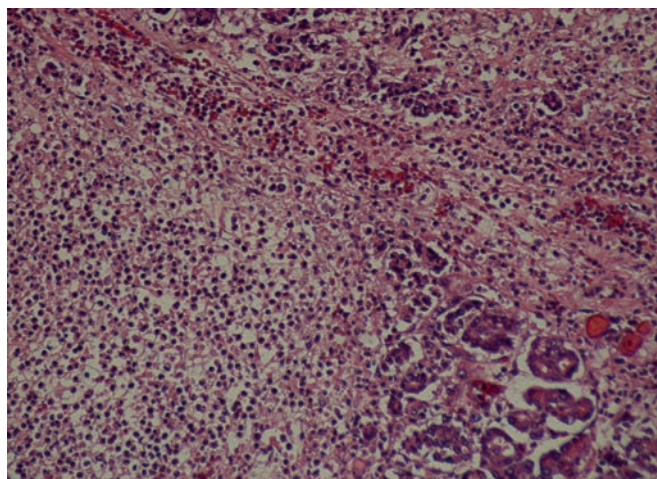


Fig. 2. Histology of the pancreas.

In paediatric patients presenting with features of vomiting and an altered level of consciousness, the clinician should also consider the following differential diagnoses: encephalitis, hepatitis, intracranial haemorrhage, intussusception, meningitis, sepsis, IEM, toxins (herbs, mushrooms), gastroenteritis and drug ingestion (salicylate, valproate).

Conclusion

Here we have described a case of Reye-like syndrome complicated by pancreatitis in an 8-year-old boy. We based our diagnosis on the following: There was a definitive clear history of aspirin administration. The child presented with profuse vomiting and clinical symptoms in keeping with Reye's syndrome stage I. The child deteriorated progressively over a period of 6 days. Postmortem findings showed extensive steatosis of the liver with enlarged mitochondria on electron microscopy. The association of Reye's syndrome complicated by pancreatitis is well documented.

The limitations of our study included a lack of metabolic screening to rule out an underlying IEM. However, children with IEM would usually present much earlier (<3 years of age^[3]) with pre-existing failure to thrive, baseline neurological sequelae and liver dysfunction lasting longer than a week in duration. Several pathology and paediatric pathology experts were consulted, who suggested different diagnoses including Reye-like syndrome, Reye's syndrome and isolated pancreatitis as cause of death. The clinical picture in this case did not fully support the diagnosis of pancreatitis. The amylase and lipase

CASE REPORT

levels were also low initially, rising later, suggesting pancreatitis as a complication, rather than the source of pathology.^[10]

Is Reye's syndrome then still a valid diagnosis? Even among experts, different opinions remain. The purpose of this article is to serve as a reminder of what is regarded to be a very old diagnosis, to create awareness of the complications following aspirin use and to remember to consider pancreatitis in children who present with Reye-like symptoms.

References

1. Belay ED, Bresee S, Holman RC, Khan AS, Shahriari A, Schonberger LB. Reye's syndrome in the United States from 1981 through 1997. *N Engl J Med* 1999;340(18):1377-1382. [<http://dx.doi.org/10.1056/NEJM199905063401801>]
2. Reye RDK, Morgan G, Baral J. Encephalopathy and fatty degeneration of the viscera: A disease entity in childhood. *Lancet* 1963;2(7311):749-752. [[http://dx.doi.org/10.1016/s0140-6736\(63\)90554-3](http://dx.doi.org/10.1016/s0140-6736(63)90554-3)]
3. Green A, Hall SM. Investigation of metabolic disorders resembling Reye's syndrome. *Arch Dis Child* 1992;67(10):1313-1317. [<http://dx.doi.org/10.1136/adc.67.10.1313>]
4. National Reye's Syndrome Foundation. Facts About Reye's Syndrome. <http://www.reyessyndrome.org/facts.html> (accessed 5 November 2013).
5. Porter JDH, Robinson PH, Glasgow JFT, Banks JH, Hall SM. Trends in the incidence of Reye's syndrome and the use of aspirin. *Arch Dis Child* 1990;65(8):826-829. [<http://dx.doi.org/10.1136/adc.65.8.826>]
6. Donald K, Hall S, Seaton C, Tanyanyiwa D. Is non-therapeutic aspirin use in children a problem in South Africa? *S Afr Med J* 2011;101(11):823-828.
7. Ellis GH, Mirkin LD, Mills MC. Pancreatitis and Reye's syndrome. *Am J Dis Child* 1979;133(10):1014-1016. [<http://dx.doi.org/10.1001/archpedi.1979.02130100038007>]
8. Orłowski JP. Whatever happened to Reye's syndrome? Did it ever really exist? *Crit Care Med* 1999;27(8):1582-1587. [<http://dx.doi.org/10.1097/00003246-199908000-00032>]
9. Hall S. Workshop on Reye's syndrome and Reye-like inherited metabolic disorders. Doncaster, UK, 14 - 15 March 2002. <http://www.reyessyndrome.co.uk/docs/PUMMILLI690910-30-10-2> (accessed 19 August 2013).
10. Srinath AI, Lowe ME. Pediatric pancreatitis. *Pediatr Rev* 2013;34:79-89. [<http://dx.doi.org/10.1542/pir.34-2-79>]