

An unusual cause of humeral fracture

M Prince, Medical Student

J van Dijk, Medical Student

A B van As, MB ChB, MMed, MBA, FCS (SA), PhD

Trauma Unit, Red Cross War Memorial Children's Hospital, Cape Town

Humeral fractures in children are relatively common. A history of trauma or suspicion of non-accidental injury will often lead the clinician to a cause. However, a number of other pathologies that can result in fractures should also be considered, particularly when there are additional associated symptoms. A case is presented of a 1-month-old child who was found to be irritable, constantly crying and barely using his upper limbs. Radiographs demonstrated a fracture of the right humerus along with a number of characteristic bone lesions that suggested a diagnosis of congenital syphilis.

Case report

A baby aged 1 month was seen at the Red Cross Children's Hospital trauma unit. He had been brought to hospital after his mother's friends noticed that he had been crying a lot and barely moving his arms, particularly his right arm, over the past 3 days. The family had not noticed any trauma. He had not vomited or had any diarrhoea, and there was no history of seizures. He was alert, well hydrated and (breast) feeding well, and this was his first admission to hospital. Delivery had been normal and he had weighed 3 850 g at birth. His mother was known to have abused drugs during the pregnancy, but other than that the family history did not reveal any problems and there was no evidence of developmental delay.

On examination, the patient was afebrile with a respiratory rate of 50/min and a pulse rate of 140/min. He was not moving either of his arms and had reduced tone in the upper limbs (pseudo-paralysis). There were no signs of meningism and the cranial nerves were all functional. Tone and power in the lower limbs were normal. Reflexes were hard to elicit. Findings on examination of the respiratory and gastrointestinal tracts and cardiovascular system were unremarkable.

A full blood count and smear indicated normocytic anaemia with a haemoglobin concentration of 8.3 g/dl, a mean corpuscular volume of 77.8 fl and an elevated white cell count of $18.62 \times 10^9/l$. The serum calcium level was normal, but a rapid plasma reagin test was positive. Radiographs of the upper limbs showed several areas with loss of density and a midshaft fracture of the right humerus (Fig. 1).

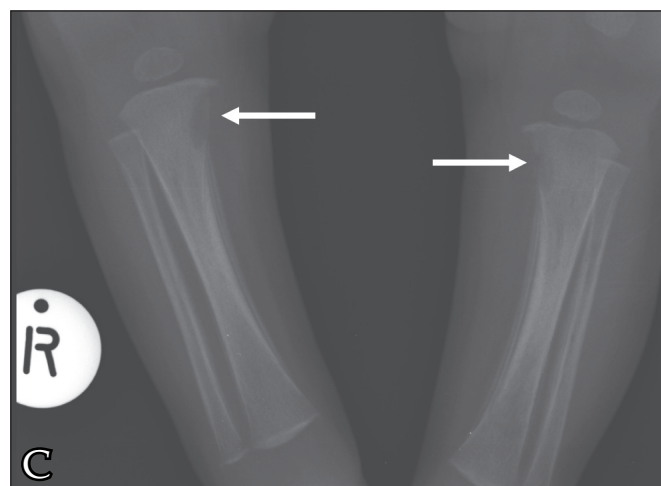
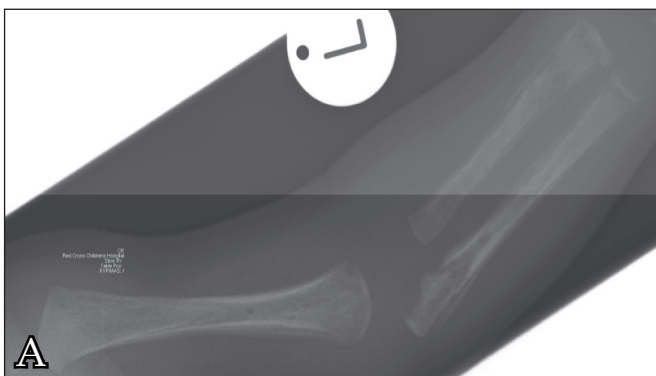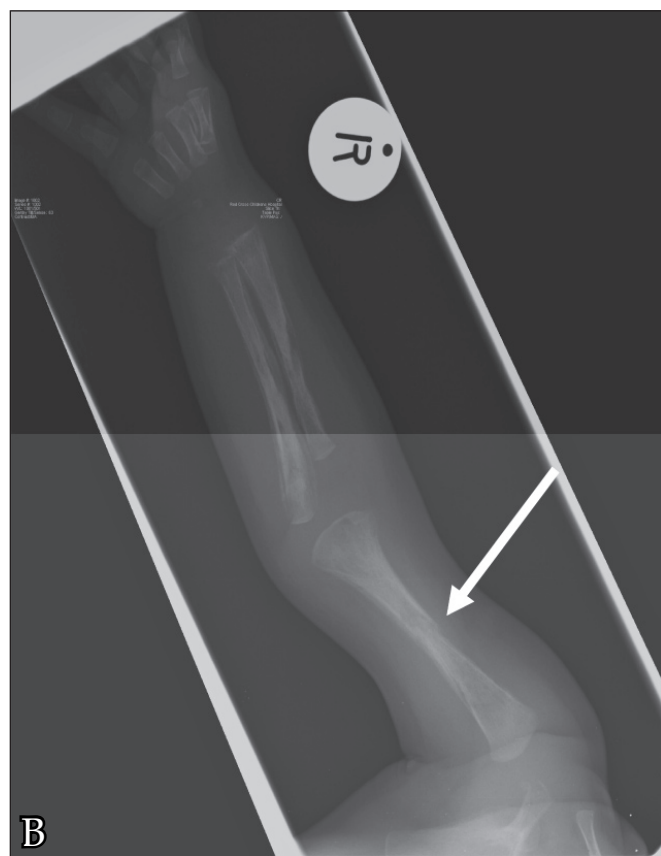


Fig. 1. A: Prominent periosteal thickening of the left humerus, radius and ulna; B: Prominent periosteal thickening of the right humerus, radius and ulna with the pathological fracture of the right humerus (arrow); and C: Wimberger's sign ('rat bite' sign) at the proximal end of each tibia (arrows).

A diagnosis of congenital syphilis was made and the baby was started on treatment with intravenous penicillin G (500 000 units 12-hourly) for 10 days. After 7 days he was able to move both arms normally, by day 8 he was moving all four limbs normally, and on day 12 he was discharged home.

Discussion

Congenital syphilis is caused by the spirochaete *Treponema pallidum* and is a relatively uncommon presentation in developed countries today. However, elsewhere in the world the health practitioner may be far more likely to encounter a case. Worldwide over 130 million children are born each year with congenital syphilis, 8 million of whom die before their first birthday.¹ Women with untreated syphilis may transmit the infection to an unborn baby at any clinical stage of their disease. However, trans-placental infection is rare before 18 weeks' gestation because the fetus is protected by the presence of a Langhans cell layer in the chorion.

The organs and structures involved in congenital syphilis are determined by the haematogenous spread of *T. pallidum* during fetal life. Clinical manifestations of the disease can be divided into those seen in the early stage (<2 years) and those seen in the late stage (>2 years). Common early clinical findings include a copper-red maculopapular rash, stomatitis and anal fissures, a syphilitic pneumonia, skeletal damage, rhinitis, hepatosplenomegaly, hair loss and exfoliation of the nails. Late findings, which tend to result from the damage caused by early systemic disease, may include notched upper central incisors, interstitial keratitis and 8th nerve damage (these three findings together comprise Hutchinson's triad), neurological complications, Clutton's joints and skeletal damage. The clinical picture, however, can vary widely between patients.

The treatment of choice is usually intramuscular aqueous procaine penicillin G, 50 000 U/kg daily for 10 days. A single injection of benzathine penicillin 50 000 U/kg may be enough to treat asymptomatic disease but will not cure neurosyphilis, which is often also present. Intrauterine death occurs in an estimated 25% of untreated cases, while stillbirths are also common.²

Bone involvement is the most common manifestation of congenital syphilis. It usually takes the form of periostitis or osteochondritis, with the femur and humerus most often involved. Wegner's sign (serrated calcification at the epiphyseal margin) along with pathological fractures and thickening of the sternal side of the clavicle may be evident on presentation. Wimberger's sign (destruction of the upper medial tibial metaphysis) is strongly indicative of congenital syphilis, although not pathognomonic as previously thought.³ However, perhaps surprisingly, such lesions usually heal completely with no residual long-term damage once appropriate treatment has been given.⁴

Conditions that may be mistaken for congenital syphilis on presentation include scurvy, osteogenesis imperfecta, rickets, idiopathic thrombocytopenic purpura, meningococcal septicaemia and congenital rubella. In particular, radiolucencies in the metaphysis of long bones and pathological fractures that mimic those seen in this patient with congenital syphilis have also been described in patients with congenital rubella, highlighting the importance of serological tests to confirm the diagnosis.³

The reasons for congenital syphilis are similar throughout the world. Lack of antenatal care is the major stumbling block in detecting maternal disease and eradicating it.⁵ Although screening pregnant women for syphilis is a simple enough goal, actually implementing such a policy can be difficult, especially in the developing world. Key elements to an effective antenatal syphilis screening programme include having an adequate workforce and facilities, good leadership and strong involvement of the community.⁶ When such screening services have been set up in parts of the developing world, they have often been extremely successful in reducing the rate of mother-to-child vertical transmission.⁷

The costs of congenital syphilis are huge, both to society in terms of medical bills and parents' time off work and to the individuals concerned in terms of high stillbirth rates and lifelong sequelae. Integrating testing for syphilis into prenatal care has therefore not surprisingly been shown to be cost-effective.⁸

References

1. World Health Organization. Neonatal and Perinatal Mortality: Country, Region and Global Estimates. 2006. http://who.int/making_pregnancy_safer/publications/neonatal.pdf (accessed 21 August 2007).
2. Fagin RD, Cherry JD. *Textbook of Paediatric Infectious Diseases*. Vol. 1. 3rd ed. Philadelphia: WB Saunders, 1992: 555.
3. Feigin RD, Cherry JD, Demmler GJ, Kaplan SL. *Textbook of Paediatric Infectious Diseases*. Vol. 2. 5th ed. Philadelphia: Saunders; an imprint of Elsevier Science, 2004: 1730, 2149.
4. Rasool MN, Govender S. The skeletal manifestations of congenital syphilis: A review of 197 cases. *J Bone Joint Surg Br* 1989; 71(5): 752-755.
5. Warner L, Rochat RW, Fichtner RR, et al. Missed opportunities for congenital syphilis prevention in an urban southeastern hospital. *Sex Transm Dis* 2001; 28: 92-98.
6. Gloyd S, Montoya P, Floriano F, et al. Scaling up antenatal syphilis screening in Mozambique: Transforming policy to action. *Sex Transm Dis* 2007; 34: S31-36.
7. Cheng JQ, Zhou H, Hong FC, et al. Syphilis screening and intervention in 500,000 pregnant women in Shenzhen, the People's Republic of China. *Sex Transm Infect* 2007; 83(5): 347-350.
8. Schackman BR, Neukermans CP, Fontain SN, et al. Cost-effectiveness of rapid syphilis screening in prenatal HIV testing programs in Haiti. *PLoS Med* 2007; 4(5): 183.